

Right Coronary Artery Dominance in Cadaveric Human Hearts in Department of Anatomy of a Medical College: A Descriptive Crosssectional Study

Nripendra Tiwari,¹ Deepesh Budhathoki¹

¹Department of Anatomy, Kathmandu Medical College and Teaching Hospital, Duwakot, Bhaktapur, Nepal.

doi: 10.31729/jnma.7432

ABSTRACT

Introduction: Cardiac coronary dominance plays a significant role in different clinical conditions and diseases of the heart. As the people of developing and developed nations are having global coronary artery diseases, it is mandatory to have knowledge of coronary artery diseases including cardiac coronary dominance. The aim of this study is to find out the prevalence of the right coronary artery dominance in cadaveric human hearts in a medical college.

Methods: A descriptive cross-sectional study was conducted among all 52 preserved hearts as well as the heart isolated from cadavers obtained from the teaching hospital. The study was conducted from 24th June, 2020 to 24th December, 2020 after obtaining ethical clearance from the Institutional Review Committee (Reference number: 2306202004). All cadaveric heart specimens were labelled with numbers and photographed for easy description of anatomical variation related to the coronary artery. Data were entered into Microsoft Excel 2007 and analysed using Statistical Package for the Social Sciences version 20.0. Point estimate at 90% Confidence Interval was calculated along with frequency and proportion for binary data.

Results: Out of 52 undissected isolated cadaveric hearts, the right cardiac dominance was found in 42 (80.76%) (71.77-89.75 at 90% Confidence Interval). The mean diameter of the right coronary artery was found to be 4.06±0.55 mm.

Conclusions: The prevalence of right cardiac dominance in isolated cadaveric hearts was similar to the studies done in a similar setting.

Keywords: *cardiac; coronary arteries; dominance.*

INTRODUCTION

The major blood supply of the heart comes from the right and left coronary arteries. Cardiac dominance is based on the artery that provides the posterior interventricular branch supplying the back of the interventricular septum. As early as 1938, Schlesinger considered the cardiac dominance supplying the posterior interventricular sulcus.¹ The global incidence of sudden cardiac death ranges from four to five million cases per year.²

Cardiac dominance plays an important role in different pathologies of the heart.³ Diseases of the coronary artery are quite common globally as well as in Nepal. It is the most common cause of death among noncommunicable diseases in Nepal.⁴ More than 70% of sudden cardiac deaths are because of coronary artery diseases.⁵ The knowledge of the coronary arteries is important for the improvement of medical and surgical facilities for patients suffering from coronary artery diseases.⁶

The aim of this study is to find out the prevalence of the right coronary artery dominance in cadaveric human hearts in a medical college.

Correspondence: Dr Nripendra Tiwari, Department of Anatomy, Kathmandu Medical College and Teaching Hospital, Duwakot, Bhaktapur, Nepal. Email: nrity2000@gmail.com, Phone: +977-9851130143.

Tiwari et al. Right Coronary Artery Dominance in Cadaveric Human Hearts in Department of Anatomy of a Medical College: A Descriptive...

METHODS

A descriptive cross-sectional study was conducted in the Department of Anatomy from 24th June, 2020 to 24th December, 2020 after obtaining ethical clearance from the Institutional Review Committee (Reference number: 2306202004), Kathmandu Medical College and Teaching Hospital, Duwakot, Bhaktapur, Nepal. All the preserved hearts, as well as obtained hearts obtained from cadavers, were included in the study whereas the decayed hearts and hearts with torn vessels were excluded from the study. A convenience sampling technique was used and sample size calculated according to the following formula:

$$n = (Z^2 \times p \times q) / e^2$$

$$= (1.645^2 \times 0.79 \times 0.21) / 0.1^2$$

$$= 45$$

Where, n= minimum required sample size Z= 1.645 at 90% Confidence Interval (CI) p= prevalence of right coronary artery dominance,

79%⁷ q= 1-p e= margin of error, 10%

The minimum calculated sample size was 45. However, a sample size of 52 was taken. All the isolated cadaveric hearts were included in the study irrespective of their age, sex and weight. The coronary arteries were traced through the epicardium and subepicardial adipose tissue. The epicardium layer of the heart was removed and coronary arteries were exposed, performing gross and microdissection for determining the dominance of the heart. Dissection was performed using instruments like pointed, blunt and toothed forceps, scalpels and straight as well as curved scissors. The dissection of cadaveric hearts was conducted in free time without hampering the teaching and learning activities at the Department of Anatomy. When the posterior interventricular artery (PIVA) was a branch of the right coronary artery, it was termed right cardiac dominance and when PIVA was a branch of the left coronary artery, it was left cardiac dominance. The balanced or codominance pattern was defined as PIVA having supply from both right and left coronary arteries. The external diameter at the origination of the right and left coronary arteries were measured using 0.01 mm sensitive digital callipers. Data was collected by a selfdesigned questionnaire in a written form to obtain the necessary information on the variables of the study.

Tiwari et al. Right Coronary Artery Dominance in Cadaveric Human Hearts in Department of Anatomy of a Medical College: A Descriptive...

The number of the preserved and dissected hearts obtained from cadavers were labelled, dissected and observed in detail, photographed for easy description. Data collected was compiled in Microsoft Excel 2007 and further analysed by Statistical Package for the Social Sciences version 20.0. Point estimate at 90% Confidence Interval was calculated along with frequency and proportion for binary data.

RESULTS

Out of 52 undissected cadavers, the right cardiac dominance was found in 42 (80.76%) (71.77-89.75 at 90% Confidence Interval) and left cardiac dominance was found in 9 (17.30%) cadaveric hearts. The balanced or codominance pattern having PIVA supply from both right and left coronary arteries was found in only 1 (1.92%) of cadaveric hearts (Figure 1).

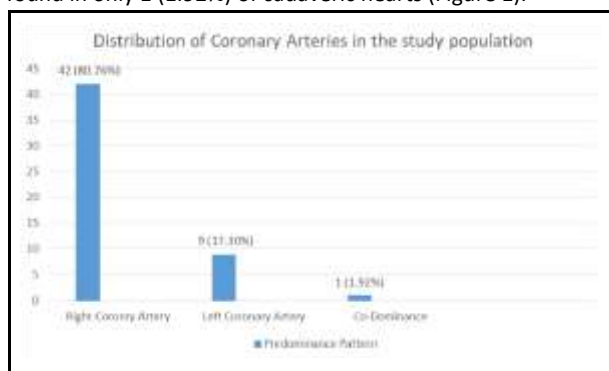


Figure 1. Coronary artery dominance among cadavers (n= 52).

The mean external diameter of the left coronary artery at its origination site was found to be 4.74±0.66 mm and that of the right coronary artery was 4.06±0.55 mm (Table 1).

Table 1. External diameter (in mm) of right coronary artery and left coronary artery (n= 52).

Arteries	Mean±Standard Deviation
Right coronary artery	4.06±0.55
Left coronary artery	4.74±0.60

DISCUSSION

The results of the present research showed that the right cardiac dominance was prevalent in 42 (80.76%), left cardiac dominance in nine (17.30%) and one (1.92%) of human hearts among 52 cadaveric sample representatives obtained from the Department of Anatomy at Tertiary Teaching Hospital. A similar result was found with 79% of predominant right cardiac dominance.⁷ Similar results with a slight difference i.e. 83.3% of the studied population with right cardiac dominance and 13.3% with left cardiac dominance.⁶ These results are not consistent with one of the study done, who found 70% of right cardiac dominance, 18.53% of left cardiac dominance and 11.43% of codominance.⁸ The cause for the difference could be due to differences in the sample size, age, and sex of

the study population. One of the study done showed only 62.5% of right cardiac dominance and 12% of left cardiac dominance.⁹ The likely cause could be due to research performed in angiographies of living subjects rather than in cadavers as done in the present study. Similarly, we researched the mean external diameter of the left coronary artery was found to be 4.74±0.60 mm and that of the right coronary artery was 4.06±0.55 mm. This finding was comparable to another study which reported the mean external diameter for the left coronary artery as 4.34±2.01 mm.¹⁰ According to the research carried out in a similar setting on coronary variations, found left coronary artery had an average outer diameter of 4.44±1.79 mm and the right coronary artery with an average diameter of only 3.32±0.79 mm.¹¹ The current study is not inconsistent with an average diameter of a right coronary artery. The cause for

the difference could be due to differences in the age, sex, humidity of the research place and embalming techniques and preservative methods of cadaveric specimens.

CONCLUSIONS

The prevalence of right cardiac dominance in isolated cadaveric hearts was similar to the studies done in a similar setting. The finding can be important for clinical and surgical interventions.

ACKNOWLEDGEMENTS

I acknowledge all supportive staff of the Department of Anatomy for their continuous support.

Conflict of Interest: None.

REFERENCES

1. Schlesinger MJ. Relation of the anatomic pattern to pathologic conditions of the coronary arteries. *Arch Pathol.* 1938;30:443. [[Full Text](#)]
2. Murray CJ, Lopez AD. Alternative projections of mortality and disability by cause 1990-2020: Global Burden of Disease Study. *Lancet.* 1997 May 24;349(9064):1498-504. [[PubMed](#) | [Full Text](#) | [DOI](#)]
3. Dakhane PS, Patil AD, Nikam VR, Karmalkar AS, Gune AR, Pote AJ. A study of coronary dominance in preserved human cadaveric heart specimens in Kolhapur region of Western Maharashtra: a dissection method. *International Journal of Anatomy and Research.* 2016;4(3):2842-6. [[Full Text](#) | [DOI](#)]
4. Nepal Health Research Council, Ministry of Health and Population and Monitoring Evaluation and Operational Research. Nepal burden of disease 2017: a country report based on the global burden of disease 2017 study [Internet]. Kathmandu (NP): Nepal Health Research Council, Ministry of Health and Population and Monitoring Evaluation and Operational Research; 2019 Apr [cited 2022 Mar 1]. Available from: http://nhrc.gov.np/wp-content/uploads/2019/04/NBoD-2017_NHRC-MoHP.pdf. [[Full Text](#)]
5. Taylor AJ, Byers JP, Cheitlin MD, Virmani R. Anomalous right or left coronary artery from the contralateral coronary sinus: "high-risk" abnormalities in the initial coronary artery course and heterogeneous clinical outcomes. *Am Heart J.* 1997 Apr;133(4):428-35. [[PubMed](#) | [Full Text](#) | [DOI](#)]
6. Vandana R, Tejesh S. Anatomical variation in branching pattern and dominance in coronary arteries: a cadaveric study. *International Journal of Anatomy and Research.* 2017; 5(1):3611-7. [[Full Text](#) | [DOI](#)]
7. Murphy ES, Rosch J, Rahimtoola SH. Frequency and significance of coronary arterial dominance in isolated aortic stenosis. *Am J Cardiol.* 1977 Apr;39(4):505-9. [[PubMed](#) | [Full Text](#) | [DOI](#)]
8. Das H, Das G, Das DC, Talukdar K. A study of coronary dominance in the population of Assam. *J Anat Soc India.* 2010;59(2):187-91. [[Full Text](#) | [DOI](#)]
9. Ortale JR, Keiralla LC, Sacilotto L. The posterior ventricular branches of the coronary arteries in the human heart. *Arq Bras Cardiol.* 2004 May;82(5):468-72, 463-7. English, Portuguese. [[PubMed](#) | [Full Text](#) | [DOI](#)]
10. Kumar A, Ajmani ML, Klinkhachorn PS. Morphological variation and dimensions of left coronary artery: a cadaveric study. *MOJ Anat Physiol.* 2018;5(4):266-70. [[Full Text](#) | [DOI](#)]
11. Fazliogullari Z, Karabulut AK, Unver Dogan N, Uysal II. Coronary artery variations and median artery in Turkish cadaver hearts. *Singapore Med J.* 2010 Oct;51(10):775-80. [[PubMed](#) | [Full Text](#)]

© The Author(s) 2022.

This work is licensed under a Creative Commons Attribution 4.0 International License. The images or other third party material in this article are included in the article's Creative Commons license, unless indicated otherwise in the credit line; if the material is not included under the Creative Commons license, users will need to obtain permission from the license holder to reproduce the material. To view a copy of this license, visit <http://creativecommons.org/licenses/by/4.0/>